



Laparoscopic nephrectomy, bench surgery, and bilateral autotransplantation in renovascular hypertension

Marquina M, García Soriano F, Esquivel P



■ ABSTRACT

Background: Experiments with renovascular hypertension were carried out by Goldblatt in 1934. He demonstrated that arterial hypertension could be caused by occluding the renal artery in dogs, and thus the name renovascular hypertension was designated. Renal arteriography is the criterion standard for confirming renovascular hypertension.

Objective: To report a complex case of renovascular hypertension due to bilateral fibrodysplasia for which laparoscopic nephrectomy, external revascularization (bench surgery) and bilateral autotransplantation were carried out in two surgeries.

Case: Patient is an 18-year-old asymptomatic male with arterial hypertension due to bilateral renal artery stenosis. After the first autotransplantation, patient progression was adequate and was corroborated by kidney scintigram and Doppler ultrasound. The second autotransplantation had the same favorable results. Blood pressure was normal from June 2006 to September 2009 with no need for antihypertensive drugs. Pathology report stated tunica media fibroplasia.

Conclusions: A case of bilateral autotransplantation in a child with Takayasu disease was found in the *Medline* archive, but the nephrectomies were open surgeries. To

■ RESUMEN

Antecedentes: Los experimentos en hipertensión renovascular (HRV), fueron realizados por Goldblatt (1934). Demostró que se puede causar hipertensión arterial al ocluir la arteria renal en perros, por lo que recibió el nombre de HRV. La arteriografía renal es el *estándar de oro* para confirmar el diagnóstico de HRV.

Objetivo: Informar sobre un caso complejo de hipertensión renovascular por fibrodysplasia bilateral, al que se le realizó nefrectomía laparoscópica, revascularización externa (cirugía de banco) y autotrasplante bilateral, en dos tiempos quirúrgicos.

Caso: Varón de 18 años de edad, asintomático, con hipertensión arterial debida a estenosis bilateral de la arteria renal. Después del primer autotrasplante, su evolución fue adecuada corroborada por gammagrama renal y ultrasonido doppler. En el segundo autotrasplante se obtuvieron los mismo resultados favorables; presión arterial normal sin tomar ningún antihipertensivo desde junio de 2006 a septiembre 2009. Resultado de patología fibroplasia de la túnica media.

Conclusiones: Al revisar el repositorio *Medline*, se encontró un caso de autotrasplante bilateral de un niño con enfermedad de Takayasu, pero las nefrectomías fueron por cirugía abierta. Consideramos que éste sería el

the best of the authors' knowledge the present report is the first on laparoscopic nephrectomy, bench surgery and bilateral autotransplantation.

Key words: Renovascular hypertension, laparoscopy, bench surgery, revascularization, autotransplantation, nephrectomy, fibrodysplasia, renal artery stenosis, Mexico.

primer informe de nefrectomía laparoscópica, cirugía de banco y autotrasplante bilateral.

Palabras clave: Hipertensión renovascular, laparoscopia, cirugía de banco, revascularización, autotrasplante, nefrectomía, fibrodysplasia y estenosis arteria renal, México.



■ INTRODUCTION

Experiments with renovascular hypertension were carried out by Goldblatt in 1934. He demonstrated that arterial hypertension could be caused by occluding the renal artery in dogs and used two models. The first, with both kidneys and one of the renal arteries occluded; the second, unilateral nephrectomy was performed and renal artery of the remaining kidney was occluded. He named this type of resulting hypertension, renovascular hypertension (RVH). Renal arteriography is the criterion standard for confirming RVH. There are other non-invasive tests that support diagnosis, based on clinical symptoms: Doppler ultrasound, kidney scintigram with captopril, and peripheral renin activity measurement, among others.

There are two types of renal artery obstruction. The most frequent type is caused by atherosclerosis and the other is caused by fibrodysplasia.¹⁻³ Medical management of hypertension is the preferred treatment for patients with medial fibroplasia, since loss of kidney function due to progressive obstruction is not common. This is similar to what happens with atherosclerosis. However, interventionist treatment is reserved for those patients whose hypertension cannot be controlled despite their taking multiple drugs. In cases of renal artery stenosis due to perimedial and intimal fibroplasia, it generally progresses into ischemic renal atrophy in which case invasive treatment is preferable.⁴⁻⁶ Angioplasty is the technique of choice in cases of fibrodysplasia. However, 30% of these patients may require surgical revascularization that is generally carried out *in situ*. However, it is possible to perform bench surgery followed by autotransplantation in complex cases in which *in situ* repair can be very challenging.⁷⁻⁹

■ CASE PRESENTATION

Patient is an 18-year-old male whose arterial hypertension (190/90 mm Hg) became apparent incidentally in February 2006. He was asymptomatic

and his case was first studied by an internist. Medical history: Diabetes mellitus on the side of his paternal grandparents and aunts and uncles; patient was a law student; no drug addiction; regular athletic activity; history of asthma requiring 200 mg Teolong at night and regular use of aerosol salbutamol; tonsillectomy at 3 years of age; no history of trauma. Physical examination was normal as were chest x-ray, electrocardiogram, echocardiogram, and kidney ultrasound. Helical angiotomography (10/02/06): right renal artery had early bifurcation and caliber reduction in one of the branches; left renal artery was single with normal caliber in the third proximal to the aorta. Both kidneys were similar in size with no alteration in excretory phase. Tc99 DTPA kidney scintigram (17 /02/06): Simultaneous perfusion, with irregular low perfusion in left kidney; perfusion first in inferior half of right kidney. Left kidney filtration 11 mL/min, right kidney 32 mL/min. Bilateral selective renal arteriography: Right renal artery with early bifurcation into two branches; caliber reduction in most of the superior branch; 85% stenosis, with uniform and normal nephrographic phase; left renal artery with uniform caliber reduction in distal two-thirds up to the hilum; 90% stenosis; and critical stenosis at the end entering the hilum, with uniform nephrographic phase (**Images 1 and 2**).

Laboratory results (9/02/06): Complete blood count normal, glycemia 86, urea 32, creatinine 1.3, creatinine clearance 140 mL/min. Cholesterol and triglycerides normal. Vanillylmandelic acid 23 mg/24 hours. Plasmatic adrenaline 7.3 pg/mL, noradrenaline 37 pg/mL, dopamine 20 pg/mL. Urinalysis normal. Laboratory (3/02/06): creatinine 3.2, urea 98 (after renal arteriography). Treatment: chlorthalidone 1x1, metoprolol 1x1, enoxaparin 40 mg 1x1, prazosin 1 mg 1x3, telmisartan 80 mg 1x3. Cardiologist with experience in hemodynamics carried out renal arteriography and decided patient was not an angioplasty candidate because of anatomical complexity and so was referred to the authors' kidney transplant team for management (revascularization). Laparoscopic left nephrectomy,

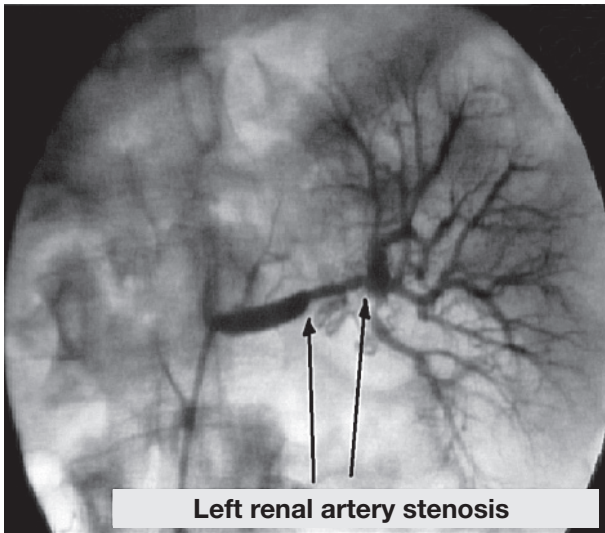


Image 1. Left renal arteriography.

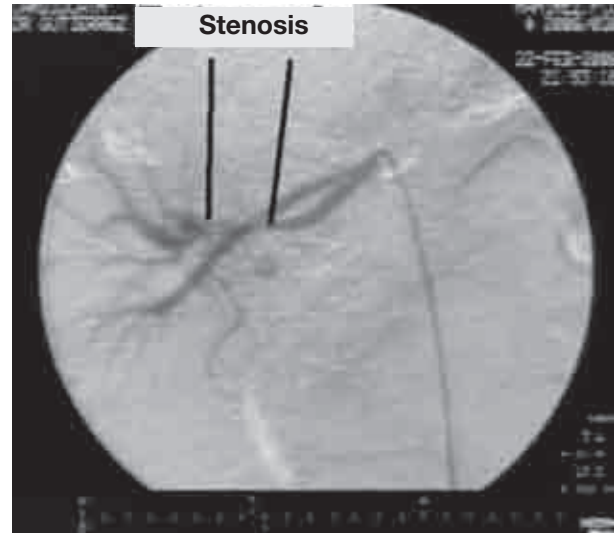


Image 2. Right renal arteriography.

bench surgery, and autotransplantation were proposed. Progression was to be observed and a repeat second surgery on the right side performed.

Technique: With patient in right lateral decubitus position, four ports (two 10 mm and two 5 mm) were introduced into left hemiabdomen dissecting donation kidney. Artery was cut where it arises from the aorta and renal vein was cut at suprarenal vein junction. The 10 mm port was extended into left iliac fossa where kidney was extracted for its perfusion with ice-cold *Custodiol* solution after which bench surgery began. Renal hilum was dissected. The entire renal artery was incised lengthwise up to its bifurcation, extending the incision to two of its branches, to one side and to the other. Renal artery was sectioned, leaving anastomosis opening prepared. *Hem-o-lok* clips were secured 10 mm from renal vein and artery stumps with 2-0 silk running suture so that the clip would not slide out of place (double-clip was used). Left iliac fossa incision was reopened and was lengthened by Gibson-type extension. Iliac vessels were dissected, end branches of hypogastric artery were tied with 0-2 silk, sectioning proximally and distally, suturing proximal stump in the bifurcation with 0-4 prolene running suture. Hypogastric graft was thus obtained and sutured in T-T form with 7-0 prolene with running suture to renal artery stump and reimplantation was begun (**Image 3**). Bench surgery ended with T-L venous anastomosis to the external iliac artery with 6-0 prolene running suture and T-L anastomosis of the neoartery to the external iliac artery with 7-0 prolene running suture. Vascular controls were released, hemostasis was checked and

ureteral reimplantation was begun using extravascular technique with 4-0 monocryl. Double pigtail ureteral catheter was left in place. A ¼ drenovac drain was placed at the surgical area and wound was sutured by planes. When procedure was finished patient was extubated and taken to intensive care unit in stable condition with abundant diuresis. Analgesics were managed with lidocaine bolus by means of epidural catheter, metamizole, and tramadol in drops. On third day patient was released from hospital with serum urea and creatinine reduction (urea 51 and creatinine 1.4) and bladder catheter was removed. High blood pressure was controlled with 20 mg telmisartan 1 x 2 and acetylsalicylic acid 1x1. On 15/05/06 high blood pressure persisted with hypoperfusion in the described zone of right kidney, and surgery similar to the one described above was indicated: laparoscopic right nephrectomy, bench surgery, and right pelvic autotransplantation. In this surgery, because of the early bifurcation of the renal artery, two arteries were obtained. Upon perfusion there was greater resistance toward the superior pole. An 8 cm segment of the left internal saphenous vein was then dissected. With the kidney immersed in ice-cold solution, the hilum was dissected, sectioning the artery for the superior pole at the bifurcation level, extending the incision to one branch and then the other. End-to-end anastomosis with the saphenous vein was carried out with 7-0 prolene running suture. Reimplantation followed with venous anastomosis to the external iliac artery with 6-0 running suture and anastomosis of the T-L inferior pole artery to the external iliac artery with 7-0 prolene

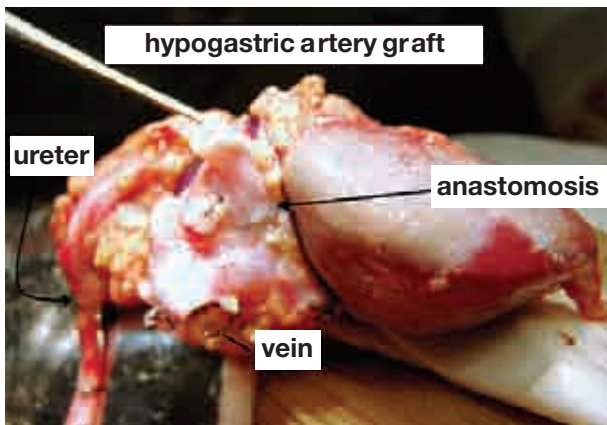


Image 3. Left kidney bench surgery.

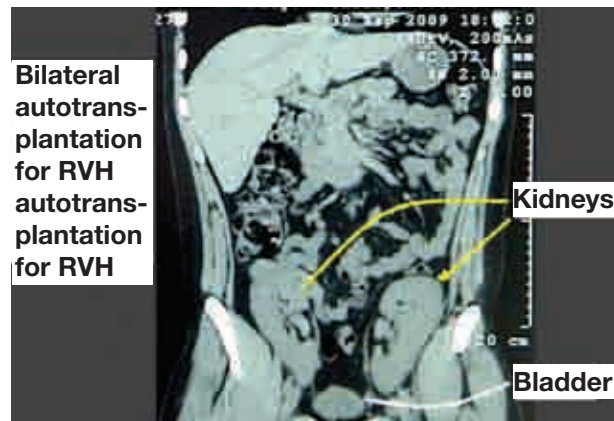


Image 4. Abdominal CT scan. Laparoscopic assisted bilateral autotransplantation for RVH at more than three years after surgery.

running suture. In the same way proximal anastomosis of the saphenous vein graft to the common iliac artery at the bifurcation level was performed. Vascular controls were released and adequate blood reperfusion was observed. Ureteral reimplantation was carried out as in the previous surgery and patient was released from the hospital on the third postoperative day with no complications.

■ PROGRESSION

After the first autotransplantation, patient progression was satisfactory and Tc99 DTPA kidney scintigram on 2/05/06 showed obvious improvement in left kidney perfusion with endogenous creatine clearance of 91 mL/min and very important deterioration of superior pole perfusion of the right kidney. Filtration was calculated at 9 mL/min and there was 25% overall kidney function. Doppler ultrasound of autotransplanted kidney showed normal flow. After the second autotransplantation, scintigram carried out on 3/08/06 showed left kidney 80 mL/min, right kidney 39.4 mL/min, and total 132 mL/min. On 18/08/06 patient was asymptomatic, not taking antihypertensive drugs, only taking acetylsalicylic acid (ASA), 1x1. In September 2009 patient was asymptomatic with blood pressure 120/70 mm Hg without medication. Pathology result was fibroplasia of the tunica media. In the first surgery hot ischemia time was 3 minutes, total ischemia time was 3 hours 30 minutes, and surgery duration was 4 hours 50 minutes. Urine production began 18 minutes after blood reperfusion, there were no accidents or complications, and bleeding was approximately 200 mL. Hospital stay was three days. In the second surgery, hot ischemia time for the superior pole was 3 minutes, 5 minutes for the inferior pole,

and total ischemia time was 220 minutes. Total surgery duration was 5 hours 10 minutes. Urine production began 15 minutes after blood reperfusion and bleeding was approximately 300 mL. There were no accidents or complications and hospital stay was three days.

Included in the present study is abdominal computed axial tomography scan at more than three years after surgery (**Image 4**).

■ DISCUSSION AND CONCLUSIONS

Approximately 70% of RVH cases are caused by atherosclerotic lesions (Novick 1996), that are generally accompanied by lesions of other arteries and the majority of cases receive non-invasive medical treatment.

The key to suspecting RVH diagnosis is:

1. Age: If disease presents before 30 years of age or after 55 years of age; fibrodysplasia for young people and atherosclerosis for older people.
2. A family history of high blood pressure: Generally associated with essential hypertension although there are reports of family histories of fibromuscular stenosis (Pannier-Moreau *et al*, 1997).
3. Recent, sudden onset hypertension: RVH should be suspected and if treated rapidly there are no chronic renal ischemic consequences.
4. Difficult-to-control hypertension.
5. There is greater association of malignant hypertension or hypertensive crisis with RVH (Simon *et al*, 1972).

Studies such as rapid-sequence excretory urography are not carried out because of poor sensitivity and

specificity. Others show renin-angiotensin-aldosterone system overactivity but because they require the suspension of antihypertensive drugs, specific diet, and samples at a specific hour, its use has been restricted. The same is true for peripheral renin, captopril tests, kidney scintigrams with and without angiotensin-converting enzyme (ACE) inhibitors, and renin in the renal vein. Other modern studies such as color Doppler ultrasound, angiography with magnetic resonance, and computed angiography facilitate lesion anatomy visualization. Sensitivity and specificity of kidney scintigram with captopril is above 90% and should be used in every case where there is high RVH suspicion after which, renal arteriography, the criterion standard test, should be carried out. Fibroplasia of the tunica media is the most frequent fibrodysplasia (75-80%) and presents with collagen rings in the principal renal artery that occasionally spread into its branches. Bilateral form is frequent, as in the present case.

In young patients it can rapidly progress into renal ischemia making invasive treatment necessary. Angioplasty is not always the adequate technique; revascularization is the better option. Due to the complexity of the present case, it was decided to utilize the advantages of laparoscopic nephrectomy, the convenience and safety of bench surgery, and to finish up with autotransplantation. In specialized centers revascularization *in situ* is the common technique. The present authors feel laparoscopic donation nephrectomy, bench surgery, and kidney transplant were safe techniques for adequate patient progression with satisfactory results.

In Vienna in 1902, the Hungarian physician Imre Ullman performed the first kidney autotransplantation in a dog. This surgery did not become feasible in humans until the beginning of the 1970s, as a response to

renovascular hypertension, aneurism, ureteral lesions or tumors. Less frequently it is performed as treatment for Moyamoya disease, Takayasu disease, renal echinococcosis, nutcracker syndrome, ureteroarterial fistula, and loin pain hematuria syndrome.^{3,5,6}

There are a few reports on autotransplantation as RVH treatment in the medical literature and only two of them were assisted by laparoscopic procedures. One is the report of a case of a boy presenting with RVH due to intimal hyperplasia in which angioplasty failed. Studies carried out in Hungary have reported on 24 autotransplantations, some of them assisted by laparoscopic procedure but none of them bilateral, as in the present case. It is possible that this case is the first laparoscopic nephrectomy, bench surgery and bilateral autotransplantation to be reported on in the literature.^{1,2,4}

BIBLIOGRAPHY

1. Langer R, Perner F. Autotransplantation of the kidney 100 years after Imre Ullmann's pioneering operation. *Orv Hetil* 2003;144(23):1115-1119.
2. Basiri A, Majidpour HS, Farrokhi F. Laparoscopy-assisted autotransplantation in child with renovascular hypertension. *J Endourol*. 2005 Oct;19(8):987-989.
3. Upadhyay J, Restrepo R, Hebert D. Long-term Outcome of Bilateral Autotransplantation in a Child With Takayasu's Arteritis. *J Urol* 2002;168(6):2566-2567.
4. Merguerian PA, McLorie GA, Balfe JW. Renal autotransplantation in children: a successful treatment for renovascular hypertension. *J Urol* 1990;144(6):1443-1445.
5. Shoskes DA, Novick AC. Surgical Treatment of Renovascular Hypertension in Moyamoya Disease: Case Report and Review of the Literature. *J Urol* 1995;153(2):450-452.
6. Castillo OA, Peacock L, Diaz M. Case report: laparoscopic repair of saccular renal-artery aneurysm. *J Endourol* 2006;20(4):260-261.
7. Ram CV. Renovascular hypertension. *Curr Opin Nephrol Hypertens* 1997;6(6):575-579.
8. Spence JD. Treatment options for renovascular hypertension. *Expert Opin Pharmacother* 2002;3(4):411-416.
9. Marekovic Z, Mokos I, Krhen I. Long-term outcome after surgical kidney revascularization for fibromuscular dysplasia and atherosclerotic renal artery stenosis. *J Urol* 2004;171(3):1043-1045.