

New evidence of the contribution of apoptosis to dengue hemorrhagic fever pathophysiology

✉ Daniel Limonta, Virginia Capó, Griselda Torres, María G Guzmán, Ledy X López, Ana B Pérez, Daniel González, Mayling Álvarez, Delfina Rosario, Rosmari Rodríguez, Joel Díaz, José L Pelegrino

Pedro Kourí Tropical Medicine Institute, IPK
Autopista Novia del Mediodía Km 6 ½, La Lisa, PO Box 601, Marianao 13, Havana, Cuba
E-mail: dlimonta@ipk.sld.cu

REPORT

ABSTRACT

Dengue is considered the most important arthropod-borne viral disease in humans and is caused by any of the four dengue virus (DENV-1-4) serotypes. DENV may cause the potentially fatal disease named dengue hemorrhagic fever/dengue shock syndrome (DHF/DSS). Although apoptosis has been implicated in DHF/DSS pathogenesis, the *in vivo* mechanisms have not been largely explored yet. In this study, formalin fixed and paraffin embedded tissues of eight fatal DHF/DSS cases from two Cuban dengue epidemics were examined, in 1997 by DENV-2 and 2001 by DENV-3. We detected DENV antigens by an immunohistochemistry assay and apoptotic cells by the TUNEL (Terminal deoxynucleotidyl Transferase-mediated dUTP nick-end labelling) technique in sections from different organs. Apoptosis was demonstrated in six out of the eight studied fatal cases. Apoptotic cells were observed in brain, intestine, liver and lung. This is the first report in literature demonstrating apoptosis in white blood cells, brain cells, and endothelial cells from the intestinal and pulmonary microvasculature from DENV infected individuals. Interestingly, it is likely that apoptotic microvascular endothelial cells were associated to plasma leakage manifested by the studied subjects. These results suggest that apoptosis may contribute to DHF/DSS pathophysiology. More studies are necessary to clarify the apoptotic cell death implications in DHF/DSS pathogenesis.

Keywords: Apoptosis, dengue, Cuba, plasma leakage, immunohistochemistry, shock

Introduction

Dengue is the most significant arthropod-borne viral disease in the world. It is estimated, fundamentally existing in tropical and subtropical areas of the world, 100 million infections and more than 20 000 deaths are caused by dengue every year. This disease is caused by any of the four dengue virus (DENV) serotypes, an RNA virus of the family *Flaviviridae*. These viruses can be produced from a benign infection, named dengue fever (DF) to the most severe forms, dengue hemorrhagic fever and dengue shock syndrome (DHF/DSS). The most important pathophysiological event in DHF/DSS is plasma leakage that causes pleural effusion, ascites and occasionally death [1, 2].

DHF/DSS pathophysiology is not entirely understood. However, a number of studies associate severe dengue with DENV sequential infections by a phenomenon named antibody-dependent enhancement, high viral loads, complement activation, and cytokines storm [1-3]. Although apoptosis (a form of programmed cell death) has been involved in dengue pathogenesis [1, 4], the mechanisms in humans have not been extensively explored [5, 6].

In the presently study, different formalin fixed and paraffin embedded tissues from fatal DENV cases from two Cuban dengue epidemics were evaluated. Considering the growing evidence of apoptosis association with dengue pathogenesis [1, 4-6], we considered that detecting apoptotic cell death in these tissues with the goal of exploring the possible contribution of apoptosis to DHF/DSS pathophysiology is important.

Results and discussion

Different formalin fixed and paraffin embedded tissues from 8 autopsies of adult subjects who had died of DHF/DSS were examined. The cases were classi-

fied as grade IV DHF/DSS according to WHO guidelines [2]. These individuals were previously diagnosed with a secondary dengue infection by serology, viral isolation in mosquito's cell culture and/or molecular detection of DENV genome. The fatal cases were from DENV-2 Santiago de Cuba epidemic in 1997, and DENV-3 epidemic in 2001 from Havana city [2]. Six autopsies were evaluated from DENV-2 epidemic and two autopsies from DENV-3 epidemic. Our study included liver, brain, intestine, lung and heart tissues. Medical records were reviewed, and microscopic/macrosopic pathological findings were collected.

Immunohistochemical assay using an indirect immunoperoxidase method with mouse monoclonal and polyclonal anti-DENV antibodies produced at our institution detected viral antigens in tissues sections [7]. The detection of apoptotic cells was carried out through the observation of characteristic morphological changes of apoptosis in cells and by the TUNEL reaction assay (*in situ* Cell Death Detection Kit, Roche Applied Science) according to the manufacturer's instructions. Positive and negative controls of both techniques were performed as it had previously been described (Figure 1A) [5, 6].

In this study, the presence of DENV antigens was detected in several hepatic midzonal necrotic areas, including some Kupffer cells, as had been documented earlier [5, 6]. Six out of the 8 studied cases had apoptotic cells, 5 subjects from DENV-2 epidemic and one case from DENV-3 epidemic. Cells with a positive TUNEL reaction and morphological changes of apoptosis were observed in sections from the liver, brain, intestine and lung (Figure 1 B, C). These results significantly increased the number of human tissues that had been involved with apoptosis in den-

1. Martina BE, Koraka P, Osterhaus AD. Dengue virus pathogenesis: an integrated view. *Clin Microbiol Rev* 2009;22:564-81.

2. Guzman MG, Kouri G. Dengue: an update. *Lancet Infect Dis* 2002;2:33-42.

3. Avirutnan P, Punyadee N, Noisakran S, Komoltri C, Thiemmea S, Auethavornanan K, et al. Vascular leakage in severe dengue virus infections: a potential role for the non-structural viral protein NS1 and complement. *J Infect Dis* 2006;193:1078-88.

4. Courageot MP, Catteau A, Despres P. Mechanisms of dengue virus-induced cell death. *Adv Virus Res* 2003;60:157-86.

5. Couvelard A, Marianneau P, Bedel C, Drouet MT, Vachon F, Henin D, et al. Report of a fatal case of dengue infection with hepatitis: demonstration of dengue antigens in hepatocytes and liver apoptosis. *Hum Pathol* 1999;30:1106-10.

6. Huerre MR, Lan NT, Marianneau P, Hue NB, Khun H, Hung NT, et al. Liver histopathology and biological correlates in five cases of fatal dengue fever in Vietnamese children. *Virchows Arch* 2001; 438:107-15.

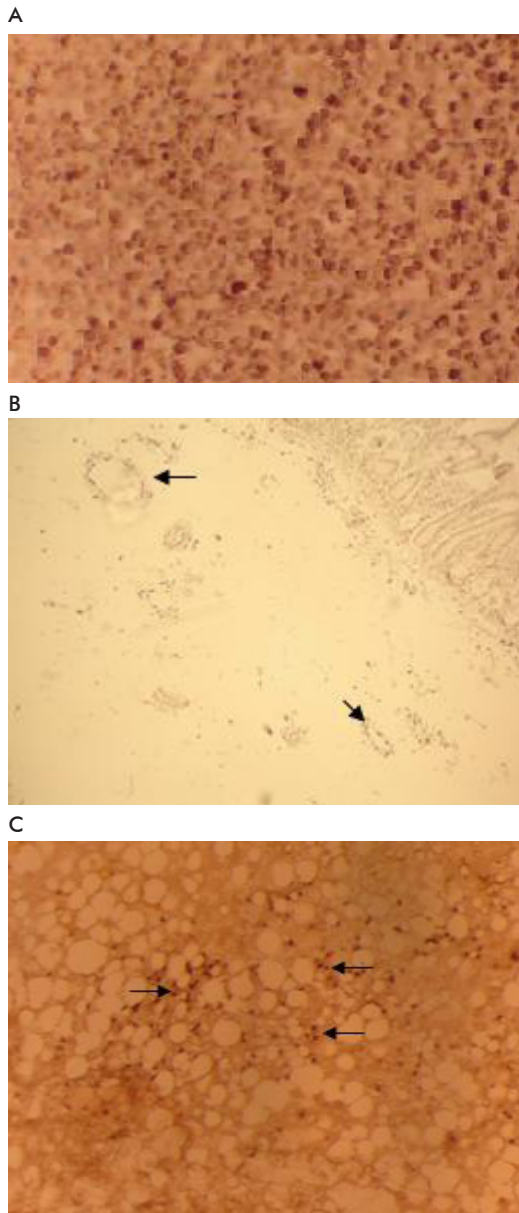


Figure 1. Detection of apoptotic cells in human samples. A) TUNEL positive control: dark blue stained nuclei in human tonsil tissue digested with DNAasa I, 200 X. B) Apoptotic endothelial cells of intestinal microvasculature (arrows) and severe intestinal wall edema are shown from case 3, 100 X. C) TUNEL positive liver cells (arrows) with large globule fatty metamorphosis of liver from case 3 are observed, 200 X.

gue disease and highlighted that our work is the largest apoptosis study carried out so far in tissues from dengue cases. In this respect, it is very relevant to mention that apoptosis in tissues from DENV cases had only been previously demonstrated in liver cells from an adult traveler in France that died of DENV-2 disease [5] and in five Vietnamese children with fatal DENV-3 infection [6].

Nuclear DNA fragmentation of numerous cerebral cells was detected in all the examined brain sections. It has been suggested that apoptosis in brain cells is a

pathogenic mechanism caused by cerebral infection of DENV during DHF/DSS taking into account studies of DENV inoculation in human neuroblastoma cell lines and mice central nervous system [4]. However, the induction of neuronal apoptosis by hypoxia has previously been documented in literature [8]. Therefore, it is very probable that hypoxia and ischemia of the central nervous system were related to the induction of apoptotic mechanisms in brain cells of the studied DHF/DSS patients.

The increased risk of severe dengue in individuals suffering from sickle cell anemia has anteriorly been reported in Cuban dengue epidemics [9]. Case 1 had sickle cell anemia, and apoptosis in cerebral tissues was demonstrated. We cannot completely exclude that abnormal characteristic S hemoglobin of sickle cell anemia has played a role. This postulate takes into account the possible induction of neuronal apoptosis by a neurotoxic mechanism of S hemoglobin that has been described previously in an *in vitro* study [10].

Interestingly, our study demonstrated apoptotic endothelial cells from the intestinal microvasculature (case 3) and pulmonary alveoli (case 7). It has been reported that DENV infection of human cell lines of endothelial cells induce apoptotic cell death [4]. However, it has also been postulated that immune mechanisms through proinflammatory mediators in serum as TNF- α and anti-NS1 (non structural protein 1 of DENV) antibodies that cross-react with surface proteins on endothelial cells may induce the apoptosis of these cells during DHF/DSS. These *in vitro* studies suggest that apoptotic cell death of endothelial cells might be associated with plasma leakage [1].

Taking into consideration our results we cannot rule out completely that DENV replication triggers apoptosis in endothelial cells, however viral antigens were not detected in lung and intestinal tissues by immunohistochemistry in our study (Table). In a previous work, the detection of DENV antigens was documented in the lung microvascular endothelium; yet, the *in situ* hybridization did not demonstrate the presence of viral RNA [11].

A recent study has associated severe dengue through plasma leakage with high levels of C5b-9 complex causing complement activation by DENV NS1 [3]. Therefore, if we consider that all the studied

Table. Dengue virus immunohistochemistry and apoptotic cell death detection in tissues from fatal dengue cases

Fatal dengue cases	DENV	Tissues	DENV IHC ^a	Tunel reaction ^b
1	DENV-3	B ^c , I ^d , H ^e	n ^f	B
2	DENV-3	I, H	n	-
3	DENV-2	B, I, Li ^g	Li	B, I, Li
4	DENV-2	Lu ^h	n	-
5	DENV-2	B, Li	Li	B
6	DENV-2	B	n	B
7	DENV-2	I, Li, Lu	n	Li, Lu
8	DENV-2	B, I, Li, Lu	n	B

^aDENV IHC: Dengue virus immunohistochemistry

^bTUNEL: Terminal deoxynucleotidyl Transferase-mediated dUTP nick-end labelling

^cB: Brain

^dI: Intestine

^eH: Heart

^fn: negative

^gLi: Liver

^hLu: Lung

7. Pelegrino JL, Arteaga E, Rodríguez AJ, González E, Frontela MD, Guzmán MG. Normalización de técnicas inmunohistoquímicas para la detección de antígenos del virus dengue en tejidos embebidos en parafina. Rev Cubana Med Trop 1997; 49:100-7.

8. Won SJ, Kim DY, Gwang BJ. Cellular and molecular pathways of ischemic neuronal death. Biochem Mol Biol 2002;35:67-86.

9. González D, Castro OE, Kouri G, Pérez J, Martínez E, Vázquez S, et al. Classical dengue hemorrhagic fever resulting from two dengue infections spaced 20 years or more apart: Havana, Dengue 3 epidemic, 2001-2002. Int J Infect Dis 2005;9:280-5.

10. Vanderveldt GM, Regan RF. The neurotoxic effect of sickle cell hemoglobin. Free Radic Res 2004;38:431-7.

11. Jessie K, Fong MY, Devi S, Lam SK, Wong KT. Localization of dengue virus in naturally infected human tissues, by immunohistochemistry and *in situ* hybridization. J Infect Dis 2004;189:1411-8.

cases had DHF/DSS, the C5b-9 complex could be involved in apoptosis induction of endothelial cells as has been demonstrated in a previous experimental study [12].

In this work, apoptosis was demonstrated in microvascular endothelial cells of lung and intestine. This is the first confirmation of apoptosis of endothelial cells in tissues from dengue cases, a prior event only described in *in vitro* studies and laboratory animals [4]. Although this finding was not shown in all the examined fatal cases with plasma leakage, this phenomenon may be associated to pulmonary edema described in case 7, and intestinal edema and ascites found in case 3 (Figure 2). Additionally, we can not exclude that apoptotic endothelial cells of intestinal microvasculature of case 3 (Figure 1 B) are related to gastrointestinal bleeding found in this individual (Figure 2), if we take into consideration a very recent mouse model of hemorrhage in dengue infection that demonstrated the apoptotic endothelial cells of subcutaneous tissues were associated with local tissue hemorrhage [13].

It is significant that case 3 suffered from type 2 diabetes mellitus. Remarkably, precedent reports in type 2 diabetes mellitus [14] have demonstrated similar dysfunctions of endothelial cells and increased production of the same cytokines showed in patients with dengue disease. These earlier diabetes mellitus studies [14] suggest that the increased risk of severe dengue in patients with type 2 diabetes mellitus may be related with abnormalities of microvascular endothelium and cytokines hiperproduction as probably happened in studied case 3. In this regard, the likely increased risk of severe dengue in diabetics was reported for the first time during Cuban dengue epidemics [2]. However, it is interesting that an increment of dengue severity has also been documented recently in diabetics from Southeast Asia [15].

In this study, the presence of apoptotic white blood cells was demonstrated within the pulmonary microvasculature of case 7. This finding supports previous reports documenting a higher number of apoptotic peripheral blood mononuclear cells in DHF than in DF (Figure 2). Additionally, very recent works of transcriptomes of peripheral blood mononuclear cells obtained during acute DENV infection indicate an activation of genes with pro-apoptotic effect [1].

Relevance of the study

So far, the present work is the largest apoptosis research performed in human tissues of DENV infected individuals. To our knowledge, this work shows for the first time apoptosis in white blood cells, brain cells, intestine and pulmonary endothelial cells from microvasculature in DENV cases. The apoptosis of microvascular endothelial cells may be associated with

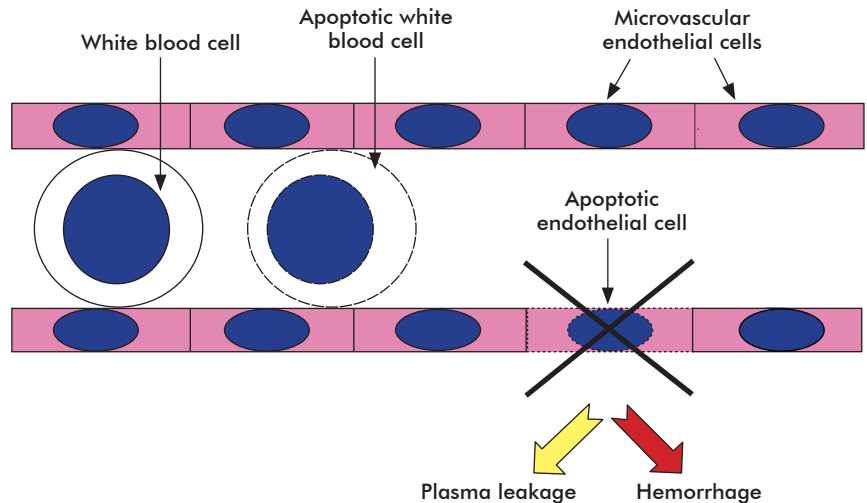


Figure 2. Contribution of apoptosis to dengue hemorrhagic fever pathophysiology. Possible plasma leakage and haemorrhage mechanism when microvascular endothelial cells undergo apoptosis. Apoptotic white blood cells may be also associated to dengue immunopathology.

plasma leakage and hemorrhage during DHF/DSS. This study suggests a risk of severe dengue likely increased in association with apoptosis in patients that suffer from type 2 diabetes mellitus and sickle cell anemia. In addition, apoptotic cerebral cells might be related to hypoxic and ischemic mechanisms during DHF/DSS. At present, a specific anti-viral therapy to dengue is not available; however, our investigation contributes to clarify the possible implications of anti-apoptotic treatment in severe dengue.

Conclusions

Summarizing, this is the largest apoptosis study in tissues of DENV infected subjects and the first work ever demonstrating apoptotic cell death in white blood cells, brain cells, intestinal and pulmonary microvascular endothelial cells from DENV cases. These results suggest that apoptosis may contribute to DHF/DSS pathophysiology.

Acknowledgments

The novel findings of this work obtained the Cuban National Academy award in 2009 and a number of colleagues were involved. We are very grateful for the assistance of researchers from the Virology Department at the Pedro Kourí Tropical Medicine Institute. They are Gissel García, Beatriz Sierra, Susana Vázquez, Maritza Pupo-Antúnez, Mayra Muné, Lidice Bernardo, and Luís Sarmiento. We also would like to thank the anatomic pathology support of Dinorah Betancourt and María C López.

12. Hughes J, Nangaku M, Alpers CE, Shankland SJ, Couser WG, Johnson RJ. C5b-9 membrane attack complex mediates endothelial cell apoptosis in experimental glomerulonephritis. *Am J Physiol Renal Physiol* 2000;278:F747-757.

13. Wu-Hsieh BA, Yen YT, Chen HC. Dengue hemorrhage in a mouse model. *Ann NY Acad Sci* 2009;1171 Suppl 1:E42-47.

14. Makino N, Maeda T, Sugano M, Satoh S, Watanabe R, Abe N. High serum TNF-alpha level in Type 2 diabetic patients with microangiopathy is associated with eNOS down-regulation and apoptosis in endothelial cells. *J Diabetes Complications* 2005;19:347-55.

15. Ong A, Sandar M, Chen MI, Sin LY. Fatal dengue hemorrhagic fever in adults during a dengue epidemic in Singapore. *Int J Infect Dis* 2007;11:263-7.